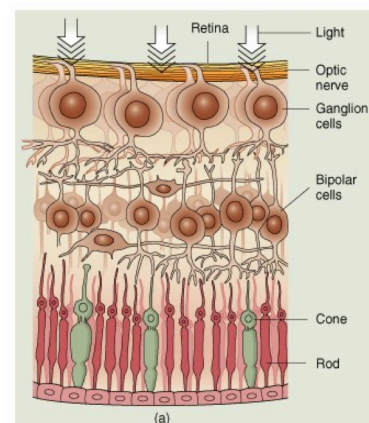
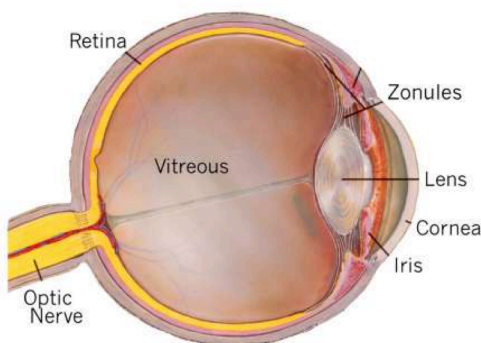


# RETINAL SURGERY

## Anatomy of the eye

The vitreous is a clear jelly like substance which fills the main cavity of the eye. Its function is to help in the development of the eye before birth, and subsequently to act as a clear optical medium to help the eye focus. The vitreous is in contact with, and adherent to the retina. The retina is a thin film of nerve tissue adherent to the inside walls of the eye.



© 2000 John Wiley & Sons, Inc.

The **retina** has a complex structure consisting of a number of layers of different types of nerve cells. The photoreceptors (rods and cones) convert light into electrical signals which are partly processed in the **retina**, before passing down the **optic nerve** to the visual cortex of the brain where the signals are converted into the image which we perceive.

When the Ophthalmologist examines the retina he is able to see and assess the health of the **optic nerve**, the **blood vessels** and the **macula**. The **macula** is the central part of the retina, and is responsible for the central, high resolution part of the vision.

**Vitreoretinal Surgery** is a specialised branch of Ophthalmic Surgery that may be used to restore vision by removing the vitreous when it becomes cloudy from degeneration, inflammation, or bleeding. Vitreoretinal surgery may also be used to repair the retina in cases where the retina becomes detached, injured, or damaged by other pathological processes.

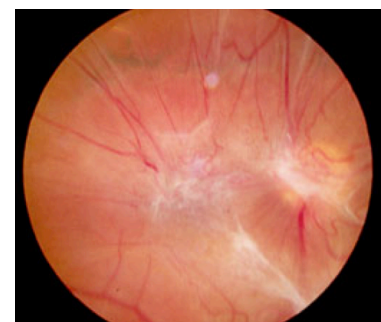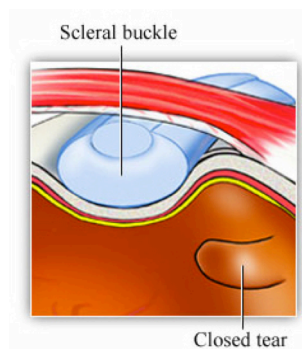
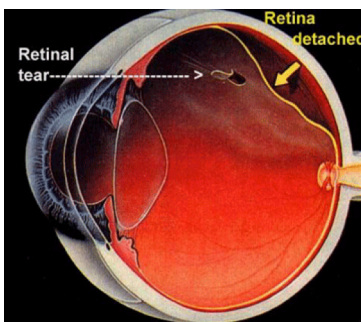


## Retinal Detachment

A detached retina usually occurs secondary to degeneration and collapse of the vitreous (**posterior vitreous detachment**), causing a tear in the retina, allowing fluid to track under the retina and lift it off the eye wall. **Posterior vitreous detachment** is very common, occurring in about two thirds of people as an ageing process, but is more common in short sighted people or after injuries, inflammation, or after some forms of eye surgery. The symptoms are **floaters** (often “like a spider”), and sometimes **flashes** in the vision. **Retinal detachment** is uncommon, occurring in about 1 per 10000 people per year (about 150 per year in South Australia).

One way of repairing a detached retina is by a **scleral buckle**. A scleral buckle is a silicone band sutured around the eye. The principle of scleral buckling is to close holes in the retina, and to relieve any traction on the retina from the vitreous. A bubble of air or gas is often placed inside the eye at the same time to help keep the retina in place, and to replace the volume of the fluid which is drained from under the retina during the operation. This results in reattachment of the retina in about 90% of cases. In the 10% of cases where the retina does not reattach, or if the retina re-detaches later the usual cause is scarring and contraction of the vitreous (called **proliferative vitreoretinopathy**). If this occurs further surgery will be required, and will usually involve vitrectomy (see below).

**Visual prognosis** following a detached retina is variable and relates most closely to vision at the time of presentation, and duration of retinal detachment. If the vision is poor at the time of presentation (usually implying detachment of the macula) the visual prognosis is poorer.



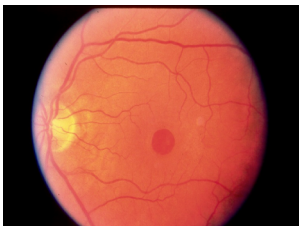Proliferative vitreoretinopathy

# Vitrectomy

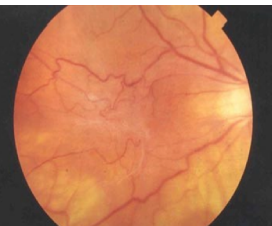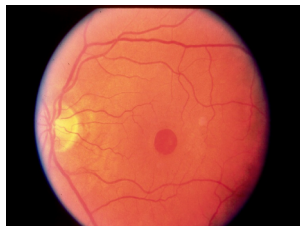This is an operation to remove the vitreous. Vitrectomy is performed to treat a number of retinal conditions including **macular hole**, **epiretinal membrane**, as well as to remove **vitreous opacities** secondary to bleeding or inflammation for example. Vitrectomy is sometimes required for some complex cases of **retinal detachment**. In these cases it is sometimes necessary to remove the **lens** from the eye (like a cataract operation), and on some occasions the vitreous is replaced with silicone oil. **Silicone oil** helps to keep the retina in position while it is healing. The oil is usually removed from the eye after 3p 6 months in another operation, but is sometimes left in the eye permanently.

**Vitrectomy** involves making **three tiny holes** in the front part of the sclera (the white part of the eye). The vitreous is removed and may be replaced by a saline fluid (the eye does not need vitreous to function), or sometimes by a bubble of air or a special gas. If a bubble is placed in the eye you will be advised of the optimum head position to keep the bubble in the best place for the retinal condition being treated.

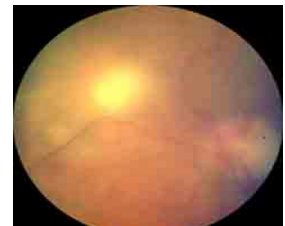Head position during sleeping hours is not too important so long as **posturing** is carried out conscientiously during waking hours. In the early postoperative period the vision is usually very blurred, especially if a bubble has been inserted into the vitreous cavity. The bubble reabsorbs spontaneously, and may take 6p 8 weeks to disappear. The vision usually improves after 3p 4 weeks once the bubble has reabsorbed above "halfp way". It usually takes about three months for retinal function to recover, and this recovery can continue for a year or two. On most occasions there are no sutures used for vitrectomy operations.



Macular hole



Epiretinal membrane



Vitreous opacity  
(inflammatory)



57 Greenhill Road  
Wayville South Australia 5034  
T 08 8273 1600  
F 08 8273 1699

Bagot House 198 North Terrace  
Adelaide South Australia 5000  
T 08 8273 1600  
F 08 8273 1699

Unit 1 279 Main South Road  
Morphett Vale South Australia 5162  
T 08 8326 6900  
F 08 8326 4494

[www.eyemedics.com.au](http://www.eyemedics.com.au)